

Advances in

SKIN & WOUND CARE

The International Journal
for Prevention and Healing

www.woundcarejournal.com

Volume 23 Number 8 August 2010

ORIGINAL INVESTIGATION

Evaluation of Vashe Wound Therapy in the Clinical Management of Patients with Chronic Wounds

Jeffrey A. Niezgoda, MD, FACHM, FAPWCA, FACEP;

Peter J. Sordi, MD, FACS; and Michel H.E. Hermans, MD

Reprinted with permission from *Advances in Skin & Wound Care* 23(8):352-257. August 2010.

Copyright © 2010 Wolters Kluwer Health | Lippincott Williams & Wilkins. All world rights reserved.

Reprinted and electronically distributed by PuriCore with permission from *Advances in Skin & Wound Care*.
For Individual Use Only - Not for Reproduction.



Wolters Kluwer | Lippincott
Health Williams & Wilkins

Evaluation of Vashe Wound Therapy in the Clinical Management of Patients with Chronic Wounds

Jeffrey A. Niezgoda, MD, FACHM, FAPWCA, FACEP;
Peter J. Sordi, MD, FACS; and Michel H.E. Hermans, MD

ABSTRACT

OBJECTIVE: To analyze if Vashe Wound Therapy (PuriCore, Malvern, Pennsylvania) is a valuable contribution to standard protocols of wound care.

DESIGN: Open, noncomparative study.

SETTING: Outpatient clinic.

PATIENTS: Thirty-one patients, primarily with venous or mixed venous/arterial leg ulcers.

INTERVENTIONS: Vashe Wound Therapy (hypochlorous acid, produced on site and on demand) was used as an adjunct to a standard wound care protocol.

MAIN OUTCOME MEASURES: Wound healing, reduction of pain, and odor.

MAIN RESULTS: At the end of the study, 86% of all lesions healed, and the average size of reduction in nonhealed wounds was 47%. Odor was present at the beginning of enrollment in 21 patients and was rated 4.58 on the visual analog scale. In all patients, the odor score at end of treatment was zero. Seventy-seven percent of all patients reported a positive pain score at the beginning of participation in the evaluation (average pain score, 4.7). At the end of the study, no patient experienced pain.

CONCLUSION: Vashe Wound Therapy is a valuable contribution to standard protocols of wound care.

ADV SKIN WOUND CARE 2010;23:2–6

INTRODUCTION

One of the more commonly used definitions of a chronic wound states that the wound “fails to progress through a normal, orderly, and timely sequence of repair” or that it “passes through the repair process without restoring anatomic and functional results.”¹ Often, an underlying compromising disease process, such as venous hypertension, is one of the primary reasons a wound becomes chronic because this type of condition may result in an excessive local inflammation response. The consequence

of such a response is deregulation of compounds that are essential for normal wound healing, resulting in, for example, an overabundance of certain metalloproteinases.^{2,3}

Microorganisms may also contribute to inflammation. When a large number of virulent bacteria are present, local wound effects, such as critical colonization, biofilm production, wound infection, and even systemic effects, such as sepsis, will occur.⁴ Generally, critical colonization is known to negatively interfere with wound healing.⁵ Wounds are very rapidly colonized, and particularly, biofilm formation is recognized to play a significant, detrimental role in the wound-healing process.^{6,7} In addition, infection is one of the reasons for wounds being painful.^{8,9}

Many ulcers tend to be malodorous. Regular tissue lysis products, such as putrescine, cadaverine, and certain short-chain fatty acids, contribute to this malodor, but bacterial contamination is known to cause the smell in different types of ulcers as well.^{10,11}

Care of chronic wounds should address a number of issues in the wound and in the patient, including treatment of the compromising factors or underlying etiology (ie, compression in patients with venous hypertension), debridement of necrosis and/or slough, and provision of a moist environment. In addition, infection needs to be prevented or treated, and contamination with microorganisms needs to be kept at a level that is manageable for the immune system.¹² Bacterial adverse effects, such as pain and odor, also should be eliminated.

Many cleansing and topical antimicrobial agents are known to be toxic to many of the cells involved in the wound-healing cascade.^{13–15} Topical antiseptics with a long history of use, such as NaOCl (Dakin solution), hydrogen peroxide (H₂O₂), acetic acid, and povidone-iodine, remain in widespread use today. These antimicrobial agents when used at typical concentrations are cytotoxic and impede wound healing and are now generally discouraged by experts for use on chronic ulcers.¹⁶ In addition, certain antimicrobial agents are known to interfere with the direct observation of the wound surface because they cause discoloration or pseudoeschar.¹⁷ Pain, whether spontaneous or caused by

Jeffrey A. Niezgoda, MD, FACHM, FAPWCA, FACEP, is Medical Director, The Center for Comprehensive Wound Care and Hyperbaric Oxygen Therapy, Aurora St Luke's Medical Center, Milwaukee, Wisconsin. Peter J. Sordi, MD, FACS, is an Attending Physician, Department of Surgery, Glen Cove Hospital, Glen Cove, New York. Michel H.E. Hermans, MD, is Independent Consultant, Medical/Clinical Affairs, 3S Consulting Group, Inc, New York, New York. **Acknowledgment:** This study was supported by PuriCore, Malvern, Pennsylvania. Submitted June 19, 2009; accepted in revised form May 6, 2010.

an agent used for wound management, may delay wound healing as well.¹⁸

Hypochlorous acid (HOCl) is produced as part of the oxidative (also called respiratory) burst pathway.¹⁹ Oxidative burst is a core reaction that occurs to kill microorganisms.²⁰ Microorganisms are engulfed (phagocytosis) by leukocytes. Nicotinamide adenine dinucleotide phosphate oxidase catalyses the formation of superoxide anions (O_2^-), which further react to form singlet oxygen, hydroxyl radicals (OH^-), and H_2O_2 .²¹ Another series of enzymes, superoxide dismutase and myeloperoxidase, catalyzes a reaction between chloride ions and H_2O_2 to yield HOCl (Figure 1),²² which reacts with further H_2O_2 to yield more singlet oxygen.

HOCl has no cellular toxicity when used in clinically effective dosages.²³ It has been widely reported that the human body regulates the levels of HOCl during the inflammatory response using its own "antioxidant defense" system utilizing scavenger molecules, such as taurine and nitrites, which neutralize HOCl and protect against oxidative damage to cells.^{24–28}

HOCl has been used extensively for surface disinfection, for the cleaning of endoscopes,^{29–31} and for food-safety applications.³²

In several, primarily in vitro, studies, HOCl has been shown to be active against many different types of microorganisms, including methicillin-resistant *Staphylococcus aureus*, vancomycin-

resistant enterococci, numerous other bacteria, viruses, and fungal spores.^{29,33–42} The agent acts very rapidly, with a kill rate of, for example, 10^8 in 1m.28s for *Bacillus subtilis* spores.²³

HOCl's small molecular size allows penetration into the cell membrane components; this influences the permeability of the cell wall and causes rupture of the cell membrane. Indeed, rapid and selective inhibition of bacterial cell division by HOCl was observed in phagocytes.⁴³

HOCl supports selective debridement and seems to reduce the amount of wound exudate. Although the exact mechanism for these observations is not known, HOCl does demonstrate fibrinolytic properties when used clinically, and exudate reduction likely correlates with decreases in bioburden. These properties have previously been demonstrated clinically, as the compound was shown to be an effective adjunct material for the management of venous leg ulcers.⁴⁴

Vashe Wound Therapy (PuriCore, Malvern, Pennsylvania) is HOCl that is produced on site and on demand, using a specific electrolyte solution and generator. The compound is the same as the one used in the leukocyte-intracellular-killing process. Consequently, Vashe Wound Therapy mimics one of the body's main ways of killing microorganisms.

A clinical evaluation was set up to study the effects of Vashe Wound Therapy on the healing of wounds in a real-world model: inclusion criteria were minimal and limited to patients' objections to participating in this evaluation and known allergies to any of the treatment methods and materials used. Specific comorbidities and/or medications did not constitute an exclusion criterion.

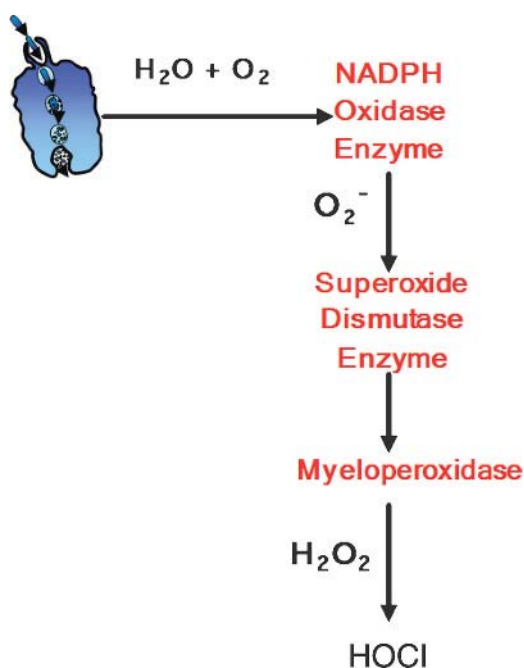
In the study, Vashe Wound Therapy was used as an adjunct agent, primarily for irrigation, cleansing, and debriding purposes, and in combination with various other wound management products and protocols accepted as standard of care.

MATERIALS AND STUDY DESIGN

Standardized wound treatment in this evaluation included establishing a proper differential diagnosis of the nature of the wound (ie, performing a detailed vascular assessment for venous leg ulcers⁴⁵), wound cleansing, and soaking (with Vashe Wound Therapy), debridement if and when necessary (based on accepted standard of care indications, such as the presence of fibrinous slough, necrotic dermis, and/or subcutaneous tissue), and using moisture-retentive dressings. Appropriate compression therapy for patients with venous insufficiency was performed as well.

Subjects were in this observational study until complete re-epithelialization or for a maximum of 3 months, whichever occurred first. Wound inspection and dressing changes were performed every 2 to 3 days for all lesions included in this evaluation.

Figure 1.
ENDOGENOUS HOCL PRODUCTION PATHWAY



Vashe Wound Therapy was integrated into the prescribed wound protocol used for a specific subject and wound. Application of Vashe Wound Therapy was accomplished by liberally soaking gauze with Vashe solution and then applying the moistened gauze directly to the wounds and the periwound areas. The Vashe Wound Therapy was allowed to dwell in contact with the tissues for 10 to 15 minutes, and then the wounds were gently scrubbed with the Vashe moistened gauze. The process was completed by a final rinse and irrigation of the tissues with Vashe Wound Therapy. Additional (sharp) debridement was performed if the gentle scrubbing was not sufficient to remove all slough and other necrotic tissue. All debridements were performed using selective codes to include but not exceed the level of the subcutaneous tissue. After debridement, a final rinse with Vashe Wound Therapy was performed. Primary and secondary dressings were applied, and appropriate compression therapy, if indicated, was then performed as ordered.

All wounds were assessed by the investigators at intervals of 1 week, in accordance with standard of care. During each assessment, standard parameters of wound healing, pain score, and odor level were evaluated. Pain was assessed using a visual analog scale (VAS), where 0 represented no pain and 10 the worst pain. Odor was also assessed using a scale of 0 to 10, where 0 represented no odor and 10 the worst odor imaginable. Patients were followed clinically and monitored as study participants until their wounds healed or, in principle, for a maximum of 3 months, whichever occurred first. However, because of continuing progress, some patients continued to be in the evaluation for an extended period. Some patients were lost to follow-up; their data are not included in the evaluation.

PATIENT POPULATION

Study participants included 31 subjects, 10 male (32%) and 21 female (68%), with 31 lesions. The average age of the subjects was 74.5 years (range, 47–96 years). Of those lesions, 25 of the ulcers were primarily venous in origin, 5 were mixed venous/arterial, and 1 wound was a nonhealing lesion, secondary to trauma, in a patient with preexisting venous pathology. Before enrolling in this evaluation, patients were managed with a variety of strategies, including occlusive dressings, topical antimicrobial ointments, and negative-pressure wound therapy.

The age of the wounds was 29 months on average (range, 1–240 months). All lesions were located on the lower leg or ankle, 21 were on the right lower extremity, and 10 on the left. The average wound size at the start of this evaluation was 22.0 cm² (range, 0.3–195 cm²). At the time of enrollment, 19 wounds (61%) showed clinical signs of infection.

RESULTS

On average, patients participated for 57 days (range, 19–203 days). A total of 29 wounds (94%) could be followed until the end of study participation. The overall average reduction in wound size was 19 cm² (range, 13.84–180 cm²).

After 30 days, 10% of all wounds had healed completely; after 60 days, 55%; and after 90 days, 23 (79%) had reached complete reepithelialization. Some patients continued to be in the evaluation for an extended period because of continuing healing progress. At the end of the study, a total of 25 of all wounds (86%) had healed (Figure 2). For wounds that did not heal completely, the average reduction in wound size was 47% (range, 43%–97%) after 3 months (90 days).

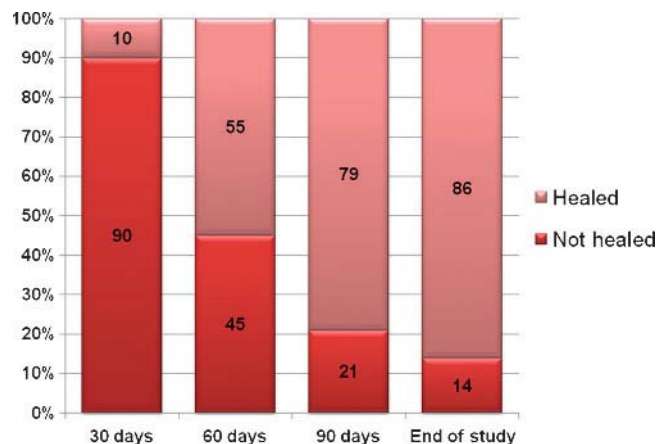
In total, 272 dressing changes were performed. Debridement was necessary at 18% of all wound care visits, but all debridement procedures performed occurred only at the time of first few dressing changes.

Odor was present at the beginning of enrollment in 21 patients and was rated 4.58 on average on the VAS (range, 1–10). At the end of the evaluation, for all patients, the odor score was 0. At the beginning of their participation in the evaluation, 77% of all patients reported a positive pain score (average score, 4.7; range, 1–10). All patients with a positive initial pain score reported a gradual reduction in pain after initiation of treatment with Vashe Wound Therapy, with complete resolution of pain for all patients by the end of the observational period.

DISCUSSION

It is estimated that chronic venous insufficiency is responsible for about 70% of leg ulcers.⁴⁶ These ulcers correlate with

Figure 2.
PERCENTAGE OF WOUNDS HEALED



significant cost and have serious negative impact on the quality of life of the patient⁴⁷; particularly, pain¹⁸ and odor have been associated with anxiety and depression.⁴⁸

Treatment of venous leg ulcers and other chronic wounds needs to be focused on both the psychological aspects the ulcer has on an individual and his/her environment and the somatic aspects, which include the primary etiology as well as local factors that prevent wound healing. As part of the latter aspect of management, prevention or treatment of infection and critical colonization plays an important role because both factors contribute to stagnation of healing.⁴

Nonsurgical treatment of ulcers has been shown to be optimal with moisture-retentive dressings.^{49,50} However, in many cases, dressings alone are not sufficient. Standard therapy should include cleansing, debridement, and management of bioburden to prevent critical colonization and infection. Although a number of medicated dressings are available, not all of them have been shown either to effectively prevent or treat infection or to do so without serious topical or even systemic adverse effects.^{51,52}

Therefore, the addition of a nontoxic but highly efficacious antimicrobial material to standard wound management would be beneficial. The authors believe that Vashe Wound Therapy fits this description very well. The wounds in this evaluation were large and chronic in nature, and 61% of them were clinically infected on enrollment. Still, with standard care and the use of Vashe Wound Therapy as an adjunct, 86% proceeded to complete reepithelialization at the end of the study.

Our reported Vashe Wound Therapy complete reepithelialization rate of 86% compares favorably to the published outcomes reported in other venous ulcer trials. Two trials comparing the use of living skin equivalents to standard of care in the management of venous ulcers report complete healing rates of 47% and 64% in the study arm patients versus 19% and 44%, respectively, for the control groups in these trials.^{53,54} In addition, significant odor (on average, 4.58 VAS score upon enrollment in 21 wounds) was completely eliminated in all patients at the end of the study, even in those that had not healed completely. Similarly, pain, present in 77% of all patients upon starting the study, completely ceased to exist in all patients at the study's conclusion.

LIMITATIONS

An observational evaluation, as opposed to a controlled clinical trial, has a number of limitations, among which patients who do not necessarily have a great deal of similarities. Results are descriptive without providing a basis for a statistical analysis or comparison.

However, a real-life evaluation allows outcome observation of a therapeutic intervention in many different clinical and

patient scenarios and provides a good basis to formulate impressions of clinical efficacy and performance. This evaluation was aimed at the latter.

CONCLUSIONS

Vashe Wound Therapy demonstrates a significant clinical benefit when added to standard wound-healing protocols in patients with venous leg ulcers. The results of this evaluation indicate rapid healing and a cessation of pain and odor in a high percentage of patients tested. ●

REFERENCES

- Lazarus GS, Cooper DM, Knighton DR, Percoraro RE, Rodeheaver G, Robson MC. Definitions and guidelines for assessment of wounds and evaluation of healing. *Wound Repair Regen* 1994;2:165-70.
- Pirilä E, Korpi JT, Korkiamäki T, et al. Collagenase-2 (MMP-8) and matrilysin-2 (MMP-26) expression in human wounds of different etiologies. *Wound Repair Regen* 2007;15:47-57.
- Raffetto JD, Khalil RA. Matrix metalloproteinases in venous tissue remodeling and varicose vein formation. *Curr Vasc Pharmacol* 2008;6(3):158-72.
- Bowler PG. Wound pathophysiology, infection and therapeutic options. *Ann Med* 2002;34:419-27.
- Sibbald RG, Contreras-Ruiz J, Coutts P, Fierheller M, Rothman A, Woo K. Bacteriology, inflammation, and healing: a study of nanocrystalline silver dressings in chronic venous leg ulcers. *Adv Skin Wound Care* 2007;20:549-58.
- Wolcott RD, Rhoads DD. A study of biofilm-based wound management in subjects with critical limb ischaemia. *J Wound Care* 2008;17:145-8, 150-2, 154-5.
- Wolcott RD, Rhoads DD, Dowd SE. Biofilms and chronic wound inflammation. *J Wound Care* 2008;17(8):333-41.
- Santy J. Recognising infection in wounds. *Nurs Stand* 2008;23(7):53-4, 56, 58 passim.
- White RJ. Wound infection-associated pain. *J Wound Care* 2009;18:245-9.
- Bowler PG, Davies BJ, Jones SA. Microbial involvement in chronic wound malodour. *J Wound Care* 1999;8:216-8.
- Poteete V. Case study: eliminating odors from wounds. *Decubitus* 1993;6(4):43-6.
- Bowler PG. The 10(5) bacterial growth guideline: reassessing its clinical relevance in wound healing. *Ostomy Wound Manage* 2003;49(1):44-53.
- Cooper ML, Boyce ST, Hansbrough JF, Foreman TJ, Frank DH. Cytotoxicity to cultured human keratinocytes of topical antimicrobial agents. *J Surg Res* 1990;48:190-5.
- Wilson JR, Mills JG, Prather ID, Dimitrijevic SD. A toxicity index of skin and wound cleansers used on in vitro fibroblasts and keratinocytes. *Adv Skin Wound Care* 2005;18:373-8.
- Zapata-Sirvent RL, Hansbrough JF. Cytotoxicity to human leukocytes by topical antimicrobial agents used for burn care. *J Burn Care Rehabil* 1993;14(2 Pt 1):132-40.
- Wang L, Bassiri M, Najafi R, et al. Hypochlorous acid as a potential wound care agent: part I. Stabilized hypochlorous acid: a component of the inorganic armamentarium of innate immunity. *J Burns Wounds* 2007;6:e5.
- Hermans MH. A general overview of burn care. *Int Wound J* 2005;2:206-20.
- McGuire L, Heffner K, Glaser R, et al. Pain and wound healing in surgical patients. *Ann Behav Med* 2006;31:165-72.
- Thomas EL, Lehrer RI, Rest RF. Human neutrophil antimicrobial activity. *Rev Infect Dis* 1988;10(Suppl 2):S450-6.
- Quinn MT, Gauss KA. Structure and regulation of the neutrophil respiratory burst oxidase: comparison with nonphagocyte oxidases. *J Leukoc Biol* 2004;76:760-81.
- Clifford DP, Repine JE. Hydrogen peroxide mediated killing of bacteria. *Mol Cell Biochem* 1982;49:143-9.
- Babior BM. The leukocyte NADPH oxidase. *Isr Med Assoc J* 2002;4(11):1023-4.
- Selkon JB. Development of a new antiseptic for treating wound infection. The Oxford European Wound Healing Course Handbook. Oxford, England: Wound Healing Institute; 2002.
- Kearns S, Dawson R Jr. Cytoprotective effect of taurine against hypochlorous acid toxicity to PC12 cells. *Adv Exp Med Biol* 2000;483:563-70.
- Li JX, Pang YZ, Tang CS, Li ZQ. Protective effect of taurine on hypochlorous acid toxicity to nuclear nucleoside triphosphatase in isolated nuclei from rat liver. *World J Gastroenterol* 2004;10:694-8.

26. Whiteman M, Hooper DC, Scott GS, Koprowski H, Halliwell B. Inhibition of hypochlorous acid-induced cellular toxicity by nitrite. *Proc Natl Acad Sci USA* 2002;99:12061-6.
27. Whiteman M, Rose P, Halliwell B. Inhibition of hypochlorous acid-induced oxidative reactions by nitrite: is nitrite an antioxidant? *Biochem Biophys Res Commun* 2003;303:1217-24.
28. Whiteman M, Rose P, Siau JL, Halliwell B. Nitrite-mediated protection against hypochlorous acid-induced chondrocyte toxicity: a novel cytoprotective role of nitric oxide in the inflamed joint? *Arthritis Rheum* 2003;48:3140-50.
29. Selkon JB, Babb JR, Morris R. Evaluation of the antimicrobial activity of a new super-oxidized water, Sterilox, for the disinfection of endoscopes. *J Hosp Infect* 1999;41:59-70.
30. Rutala WA, Weber DJ. Uses of inorganic hypochlorite (bleach) in health-care facilities. *Clin Microbiol Rev* 1997;10:597-610.
31. Fukuzaki S. Mechanisms of actions of sodium hypochlorite in cleaning and disinfection processes. *Biocontrol Sci* 2006;11:147-57.
32. Guentzel JL, Liang Lam K, Callan MA, Emmons SA, Dunham VL. Reduction of bacteria on spinach, lettuce, and surfaces in food service areas using neutral electrolyzed oxidizing water. *Food Microbiol* 2008;25:36-41.
33. Loshon CA, Melly E, Setlow B, Setlow P. Analysis of the killing of spores of *Bacillus subtilis* by a new disinfectant, Sterilox. *J Appl Microbiol* 2001;91:1051-8.
34. Martin MV, Gallagher MA. An investigation of the efficacy of super-oxidised (Optident/Sterilox) water for the disinfection of dental unit water lines. *Br Dent J* 2005;198:353-4; discussion 347.
35. Melly E, Genest PC, Gilmore ME, et al. Analysis of the properties of spores of *Bacillus subtilis* prepared at different temperatures. *J Appl Microbiol* 2002;92:1105-15.
36. Middleton AM, Chadwick MV, Sanderson JL, et al. Comparison of a solution of super-oxidized water (Sterilox) with glutaraldehyde for the disinfection of bronchoscopes, contaminated. *J Hosp Infect* 2000;45:278-82.
37. Park GW, Boston DM, Kase JA, Sampson MN, Sobsey MD. Evaluation of liquid- and fog-based application of Sterilox hypochlorous acid solution for surface inactivation of human norovirus. *Appl Environ Microbiol* 2007;73:4463-8.
38. Prince EL, Muir AV, Thomas WM, Stollard RJ, Sampson M, Lewis JA. An evaluation of the efficacy of Aqualox for microbiological control of industrial cooling tower systems. *J Hosp Infect* 2002;52(4):243-9.
39. Sampson MN, Muir AV. Not all super-oxidized waters are the same. *J Hosp Infect* 2002;52:228-9.
40. Shetty N, Srinivasan S, Holton J, Ridgway GL. Evaluation of microbicidal activity of a new disinfectant: Sterilox 2500 against *Clostridium difficile* spores, *Helicobacter pylori*, vancomycin resistant *Enterococcus* species, *Candida albicans* and several *Mycobacterium* species. *J Hosp Infect* 1999;41:101-5.
41. Walker JT, Bradshaw DJ, Fulford MR, Marsh PD. Microbiological evaluation of a range of disinfectant products to control mixed-species biofilm contamination in a laboratory model of a dental unit water system. *Appl Environ Microbiol* 2003;69:3327-32.
42. Zinkevich V, Beech IB, Tapper R, Bogdarina I. The effect of super-oxidized water on *Escherichia coli*. *J Hosp Infect* 2000;46:153-6.
43. McKenna SM, Davies KJ. The inhibition of bacterial growth by hypochlorous acid. Possible role in the bactericidal activity of phagocytes. *Biochem J* 1988;254:685-92.
44. Selkon JB, Cherry GW, Wilson JM, Hughes MA. Evaluation of hypochlorous acid washes in the treatment of chronic venous leg ulcers. *J Wound Care* 2006;15:33-7.
45. Sieggreen M. Lower extremity arterial and venous ulcers. *Nurs Clin North Am* 2005;40:391-410.
46. Abbade LP, Lastoria S. Venous ulcer: epidemiology, physiopathology, diagnosis and treatment. *Int J Dermatol* 2005;44:449-56.
47. Guarnera G, Tinelli G, Abeni D, Di Pietro C, Sampogna F, Tabolli S. Pain and quality of life in patients with vascular leg ulcers: an Italian multicentre study. *J Wound Care* 2007;16(8):347-51.
48. Jones J, Barr W, Robinson J, Carlisle C. Depression in patients with chronic venous ulceration. *Br J Nurs* 2006;15(11):S17-23.
49. Harding K, Cutting K, Price P. The cost-effectiveness of wound management protocols of care. *Br J Nurs* 2000;9(19 Suppl):S6, S8, S10 passim.
50. Meaume S, Vallet D, Morere MN, Téot L. Evaluation of a silver-releasing hydroalginate dressing in chronic wounds with signs of local infection. *J Wound Care* 2005;14:411-9.
51. Lim KS, Tang MB, Goon AT, Leow YH. Contact sensitization in patients with chronic venous leg ulcers in Singapore. *Contact Dermat* 2007;56:94-8.
52. Friederich N, Muller W. Massive iodine absorption after joint irrigation-suction drainage with PVP-iodine (Betadine) [in German]. *Z Unfallchir Versicherungsmed* 1992;85(2):74-80.
53. Falanga V, Sabolinski ML. A bilayered living skin construct (APLIGRAF) accelerates complete closure of hard-to-heal venous ulcers. *Wound Repair Regen* 1999;7:201-7.
54. Sabolinski ML, Alvarez O, Auletta M, Mulder G, Parenteau NL. Cultured skin as a 'smart material' for healing wounds: experience in venous ulcers. *Biomaterials* 1996;17(3): 311-20.

The Powerful Nature of Wound Therapy



A clinically proven solution for cell-friendly and effective wound cleansing, debridement irrigation, and dressing management.

Make Vashe Wound Therapy a part of your dermal defense strategy.

Contact us today to learn more:

1.866.918.2743

woundcare@puricore.com

vashe
wound therapy

PuriCore, Inc. • 484.321.2700 • www.puricore.com